



Decubital Ischemic Fasciitis/Atypical Decubitus Fibroplasia- A Pseudosarcomatous Lesion Commonly Presented as a Sarcoma: Case Report and Brief Review of Literature

M. Phuong Truong*, Michael Noeske, Lawrence Okumoto, Irfan Oymagil, Allison Arcuri, Simone Martin, and Mohamed Aziz

Department of Pathology, American University of the Caribbean School of Medicine, USA

Abstract

Decubital ischemic fasciitis is a rare disease process characterized by pseudosarcomatous fibroblastic proliferation. The disease process is most commonly observed in elderly debilitated or immobilized patients. Its pathophysiology is characterized by degeneration and regeneration of mitotically active fibroblasts. Due to its histologic appearance, proximity to bone, and patient population, decubital ischemic fasciitis is occasionally mistaken for a soft tissue sarcoma. We report a case of this rare condition, diagnosed utilizing magnetic resonance imaging and subsequent core needle biopsy with microscopic evaluation. We also discuss the importance of early and accurate diagnosis in patients suspected of having this condition, as it is vital to rule out the potentially malignant soft tissue sarcoma, while also utilizing effective quaternary prevention and avoiding overtreatment in patients with benign decubital ischemic fasciitis.

Keywords: Ischemic; Fasciitis; Fibroplasias; Pseudosarcomatous; Degenerative; Regenerative

Abbreviations

DIF: Decubital Ischemic Fasciitis; ADF: Atypical Decubital Fibroplasia; MRI: Medical Resonance Imaging; IHC: Immunohistochemistry

Introduction

Decubital Ischemic Fasciitis (DIF) also termed as “atypical decubital fibroplasia” (ADF), is a distinctive pseudosarcomatous fibroblastic proliferation occurring primarily, but not exclusively, in physically debilitated or immobilized patients. Ischemic fasciitis is a type of reparative or regenerative response to various types of ischemia, notably seen in bedridden or debilitated elderly patients at pressure points. It is a non-neoplastic proliferation that belongs to a group of pseudosarcomatous lesions including nodular fasciitis, proliferative fasciitis, and proliferative myositis [1]. Decubital ischemic fasciitis often occurs in the 7th and 8th decade of life. The pathogenesis of ischemic fasciitis is

intermittent ischemia that is followed by tissue breakdown and necrosis with subsequent regenerative changes [2]. This further explains the predominant location of ischemic fasciitis: in close proximity to the bone near bony prominences, and in patients who are physically debilitated or immobilized. Reports have shown decubital ischemic fasciitis arising in the chest wall, shoulder region, sacrococcygeal region, vulvogenital region, and rarely, the legs [2,3]. Decubital ischemic fasciitis can be misdiagnosed as sarcomatous lesions such as epithelioid sarcoma, myxofibrosarcoma, or myxoid liposarcoma due to its similar clinical presentation and histologic findings. Therefore, it is important to distinguish these reactive non-neoplastic lesions from truly sarcomatous ones in order to prevent misdiagnosis and aggressive superfluous treatment.

Case Presentation

We report a case of an 85-year-old female who presented with an ill-defined, painless and firm 5cm mass on her right arm involving the deep subcutis, adjacent to skeletal muscle, and fascia with no skin ulceration. The mass was noted three weeks earlier, following a recent complicated hip replacement surgery that resulted in the patient undergoing prolonged bedrest. Sonography of the right arm region using 12-MHZ linear probe showed a hypoechoic lobulated mass in the subcutaneous plane, and Color Doppler examination showed minimal vascularity of the lesion. Magnetic resonance imaging (MRI), showed a 5 cm mass-like lesion, which was isointense compared to muscle on the T1W images, but hyperintense on the T2W images. After administration of gadolinium, low peripheral enhancement was seen in the subcutaneous and muscular tissues. The bone adjacent to the affected soft tissue was not involved. Although the imaging studies were suggestive of Decubital Ischemic Fasciitis, a sarcomatous lesion was not ruled out and histologic examination was recommended.

Submitted: 15 June 2020 | **Accepted:** 30 June 2020 | **Published:** 02 July 2020

***Corresponding author:** M. Phuong Truong, Department of Pathology, American University of the Caribbean, 1 University Drive at Jordan Road Cupecoy, St. Maarten. Tel: +1-623-986-8956; Email: maitruong@students.aucmed.edu

Copyright: © 2020 Truong MP, et al. This is an open-access article distributed under the terms of the Creative Commons Attribution License, which permits unrestricted use, distribution, and reproduction in any medium, provided the original author and source are credited.

Citation: Truong MP, Noeske M, Okumoto L, Oymagil I, Arcuri A, et al. (2020) Decubital Ischemic Fasciitis/Atypical Decubitus Fibroplasia- A Pseudosarcomatous Lesion Commonly Presented as a Sarcoma: Case Report and Brief Review of Literature. JSM Clin Cytol Pathol 2: 3.

A tissue core biopsy of the mass was performed and showed highly atypical spindle cell proliferation with features suggestive of Decubital Ischemic Fasciitis, but a more advanced sarcomatous lesion could not be ruled out. Excision of the mass was recommended for definitive diagnosis. The mass was surgically removed and in low power microscopic examination, it showed a lobular configuration, and was characterized by zones of fibrinoid necrosis and a prominent myxoid stroma rimmed by ingrowing, ectatic, thin-walled vascular channels (Figure 1 A&B). High power examination revealed atypical, enlarged, degenerated fibroblasts and myofibroblasts with abundant basophilic cytoplasm, large hyperchromatic, smudged nuclei, and prominent nucleoli (Figure 1 C&D). Microscopic examination showed no nuclear atypia sufficient for malignant diagnosis. The architectural atypia was accepted as a feature commonly seen in many reactive non-neoplastic conditions. A sarcomatous lesion was ruled out and a diagnosis of Decubital Ischemic Fasciitis was rendered.

Six months later, patient returned to normal activities. The patient was followed for 9 months with no evidence of recurrence or significant findings, after which she was lost to follow up.

Discussion

The clinical and histologic features of decubital ischemic fasciitis indicate it is a unique type of pressure sore displaying degenerative and regenerative features distinct from a decubitus

ulcer. Ischemic fasciitis can be further differentiated from conventional fasciitis by its biphasic appearance featuring an outer fringe of mitotically active fibroblasts and capillaries circumscribing a central area of liquefactive and focally coagulative necrosis [3]. Furthermore, lesions in decubital ischemic fasciitis are considerably larger than lesions observed in conventional fasciitis.

Because decubital ischemic fasciitis is typically seen in elderly patients with limited physical abilities, a correct diagnosis is imperative in order to prevent aggressive excessive management that would potentially exacerbate the patient's decline. As a result, clinicians should be aware of the parallels drawn between atypical decubital fibroplasia and soft tissue sarcomas. A clinical presentation of a wheelchair bound, immobilized, debilitated or bedridden elderly patient with a soft tissue mass should initially raise suspicion for a non-neoplastic entity. Furthermore, the distinctive combination of a central necrotic mass with a myxoid stroma at the location of a bony prominence is confirming of decubital ischemic fasciitis [4]. When management is indicated, however, surgical resection has been used and is appropriate.

Frequently misdiagnosed as a sarcoma due to their size, atypical features, and proximity to bone, recognition of decubital ischemic fasciitis in elderly and debilitated patients is important, as it will avoid misdiagnosis as a sarcoma and prevent unnecessary aggressive treatment. It was first coined as "atypical decubital

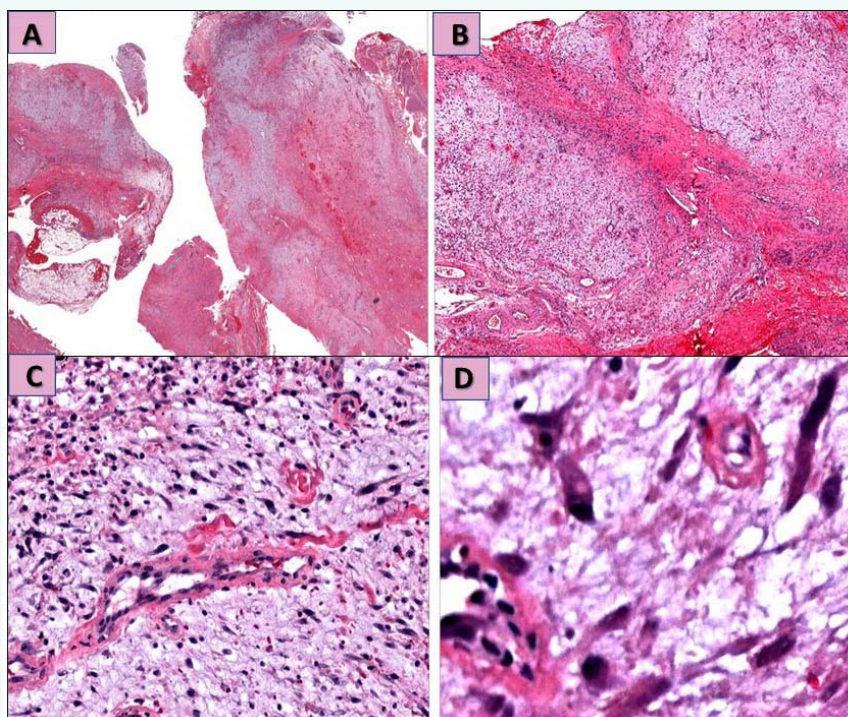


Figure 1 Microscopic examination of the arm mass.

Figure 1A&B: Low power magnification shows lobular configuration, with zones of fibrinoid necrosis and a prominent myxoid stroma rimmed by ingrowing, ectatic, thin-walled vascular channels (H&E stain X20 and X40).

Figure 1C&D: High power magnification shows atypical, enlarged, degenerated fibroblasts and myofibroblasts with abundant basophilic cytoplasm, large hyperchromatic, smudged nuclei, and prominent nucleoli (H&E stain X60 and X100).



fibroplasia” in 1992 by Montgomery et al. [5] who at the time described pseudosarcomatous fibroblastic proliferations in 28 patients, most of whom were notably bedridden. Both terms are nowadays used interchangeably to describe a deep subcutaneous lesion that is often found at pressure points, commonly in non-ambulatory elderly populations. [6]. The histologic appearance of decubital ischemic fasciitis makes it a point of interest as it closely resembles that of soft tissue sarcoma, such as myxofibrosarcomas, myxoid liposarcomas, and epithelioid sarcomas.

Myxofibrosarcomas are commonly seen in elderly patients and often resemble myxoid liposarcomas, as they both histologically exhibit myxoid and multinodular growth. Because myxofibrosarcomas show proliferative activity, an infiltrative growth pattern, and a myxoid stroma [7], they resemble the histology of atypical decubital fibroplasia- a lesion that is also classically seen in elderly populations. The overlap between these histologic appearances can be a cause of diagnostic errors. Similarly, epithelioid sarcoma is another type of malignant tumor that can be misdiagnosed as atypical decubital fibroplasia. Both masses can present as an ill-defined deep subcutaneous nodule involving the fascia or tendon and both characteristically have a necrotic center [7,8]. Epithelioid sarcomas often involve the upper extremity. In comparison, our reported patient presented with an ill-defined deep subcutis mass on her right arm. Yassin Nayel et al reported a very interesting case of a myxoid chondrosarcoma that was closely similar histomorphologically to myxoid liposarcoma and myxoid leiomyosarcoma in addition to other myxoid non-neoplastic lesions. In their reported case, molecular testing was the final diagnostic determinant as IHC studies were not conclusive [9].

It is important to note, however, that not every case is associated with debilitation as decubital ischemic fasciitis may present in patients who have no debilitation or ambulatory restrictions. Such was the case seen in a 55-year-old woman with no history of bed rest or debilitation, who presented with a 5x5cm irregular brown yellow, indurated soft to hard tissue mass over her left gluteal region and microscopic analysis was consistent with ischemic fasciitis [1]. Thus, it is important that these masses be biopsied and further analyzed cytologically and histologically.

It is our hope that this report raises awareness of pathologists and clinicians of the diagnosis and management of Decubital Ischemic Fasciitis, and continued investigation drives further development of efficacious diagnosis and safe treatments for improving patient outcomes.

Acknowledgements

Special thanks to Shahed Khalefih, Nahal Torabi, and Aldrige Awuku, MD candidates, American University of the Caribbean for their assistance in reviewing the final version of this manuscript.

References

1. Wader J, Gajbi N, Kumbhar S. Ischaemic fasciitis: a very rare entity with unusual presentation. *J Clin Diagn Res.* 2013;7(12):2952-2953. doi:10.7860/JCDR/2013/5942.3687
2. Padmanaban, D., Rangasami, R., Chandrasekharan, A., & Swaminathan, R. (2011). Decubital ischemic fasciitis presenting in an unusual location. *Radiology Case Reports*, 6(4), 590. Retrieved from <https://www.ncbi.nlm.nih.gov/pmc/articles/PMC4899984/>
3. Scanlon R, Kelehan P, Flannelly G, et al. Ischemic fasciitis: an unusual vulvovaginal spindle cell lesion. *Int J Gynecol Pathol.* 2004;23:65-67.
4. Perosio PM, Weiss SW. Ischemic fasciitis: A juxta-skeletal fibroblastic proliferation with a predilection for elderly patients. *Mod Pathol.* 1993;6:69-72.
5. Montgomery EA, Meis JM, Mitchell MS, Enzinger FM. A typical decubital fibroplasias. A distinctive fibroblastic pseudotumor occurring in debilitated patients. *Am J Surg Pathol.* 1992;16:708-15. [PubMed] [Google Scholar]
6. Ilaşlan, H., Joyce, M., Bauer, T., & Sundaram, M. (2006). Decubital Ischemic Fasciitis: Clinical, Pathologic, and MRI Features of Pseudosarcoma. *American Journal of Roentgenology*, 187(5), 1338-1341. Retrieved from <https://www.ajronline.org/action/showCitFormats?doi=10.2214/AJR.05.0688>
7. van Vliet, M., Kliffen, M., Krestin, G.P. et al. *Eur Radiol* (2009) 19: 1499. <https://doi.org/10.1007/s00330-008-1292-3>
8. Oguejiofor LN, Sheyner I, Stover KT, Osipov V. Ischemic fasciitis in an 85-year-old debilitated female. *J Am Med Dir Assoc.* 2011;12:240-41.
9. Nayel Y, Jackson G, Taylor M, Varney J, Aziz M, et al. (2020) Extraskelatal Myxoid Chondrosarcoma in Comparison to Myxoid Liposarcoma- Case Report of a Challenging Diagnosis and Brief Review of the Literature. *JSM Clin Cytol Pathol* 5: 5.