



Primary Hydatid Cyst in the Subcutaneous Tissues of the Neck in the Sub-Occipital Area: An Unusual Site of Hydatid Cyst

Manucher Aghajanzadeh^{1*}, Sharokh Yousefzadeh Jabock²,
Hossein Hemmati¹, Mohammad Sadegh Esmaili Delshad², and Piroze Samidost¹

¹Department of Thoracic and General Surgery, Guilan University of Medical Sciences, Iran

²Department of Neurosurgery, Guilan University of Medical Sciences, Iran

Abstract

Introduction: Hydatid cyst is a condition commonly affecting liver and lungs caused most commonly by *Echinococcus granulosus* where as musculoskeletal or subcutaneous hydatidosis is very rare. and Usually are secondary and resulting from the spread of cysts from other organs, either spontaneously rupture or after spreading from operations for hydatidosis in other regions.

Case Presentation: We present an unusual case of a primary hydatid cyst found in the subcutaneous scalp tissue under occipital region in a 36 year man. Clinical presentation of patient was a huge cystic mass. Ultrasound findings revealed a cyst lesion in the posterior aspect of neck under the occipital region. MRI show a cystic lesion. We removed the entire part of cyst lesion surgically. Macroscopic and microscopic histopathological examinations confirmed the diagnosis of subcutaneous hydatid cyst.

Conclusion: In regions where hydatid disease is endemic, a cystic lesion in any part of the body should be considered a hydatid cyst. The best treatment is surgery and total evacuation of the cyst elements without any spillage of cyst contained and postoperative albendazole therapy.

Introduction

Hydatid disease is a parasitic infection caused by the tapeworm *Echinococcus granulosus*. This parasitic disease is a significant public health concern in endemic country [1]. Hydatid disease is endemic in the Middle East, India, Africa, South America, New Zealand, Iran, Australia, Iran, Turkey and Southern Europe [1-4].

Life cycle of *Echinococcus* involves two hosts, one definitive carnivore host (dogs, cats and certain wild carnivores) and the other intermediate herbivore host (sheep, goats, swine, small rodents and other wild herbivores) [5]. Humans act as an accidental intermediate host is infected after ingesting viable oncosphere-containing eggs, which have been shed in the feces of the definitive host [2]. But the liver and lungs are the main locations [2,3]. Various parts of body may be involved with hydatid cyst but Hydatid cyst develops most frequently in the

liver (65%), the lungs (25%), and the remaining 10% occurs in muscle, spleen, bones, kidneys, brain, eye, heart, subcutaneous and pancreas [2,6,7]. Occurrence of hydatid cyst is extremely rare in the head and neck region even in endemic areas where hydatid cyst infestation is frequent. Only a few cases of hydatid cyst located in head and neck have been reported in the literature [5,7]. We will present our experience in treating a case of hydatid cyst located in the subcutaneous neck area, which is considered one of the few cases published due to the relative rarity of the disease in the fore mentioned anatomical location

Case Presentation

A 36 year old man, who is not known to have any medical history, presented to the head, neck and maxillofacial Surgery department of Poorsina and Razi hospital, with a chief complaint of a posterior under occipital and neck swelling, noted about 4 month back. The general condition of the patient was good; he had no history of fever or weight loss. The patient lived almost in a city near the mountain. He reported that the swelling was gradually increasing in size with pain.

Clinical examination revealed a well-defined, non-tender posterior and upper neck under occipital region swelling of about 8 cm in diameter, other part of neck and scalp was normal. Systemic examination of chest, abdomen and extremities was unremarkable. On the ultrasonography (USG), a complex, cystic lesion (10x4x5 mm) with septet and debris in the subcutaneous adipose tissue was detected. On CT-scs in sagittal and coronal view, a cystic lesion was presented in the base of skull posterior of neck (Figures 1-3). Anti-faciola tests was negative. Upon the clinical diagnosis of the subcutaneous cyst, the patient underwent surgery in prone position under general anesthesia. After prep and drape and aspiration 30 CC clear fluid from cyst cavity (Figure

Submitted: 20 March 2019 | Accepted: 22 May 2019 | Published: 24 May 2019

*Corresponding author: Manucher Aghajanzadeh, Department of Thoracic and General Surgery, Guilan University of Medical Sciences, Rasht, Iran, Tel: +98-9113-311-881; Email: maghajanzadeh2003@yahoo.com

Copyright: © 2019 Aghajanzadeh M, et al. This is an open-access article distributed under the terms of the Creative Commons Attribution License, which permits unrestricted use, distribution, and reproduction in any medium, provided the original author and source are credited.

Citation: Aghajanzadeh M, Jabock SY, Hemmati H, Esmaili Delshad MS, Samidost P (2019) Primary Hydatid Cyst in the Subcutaneous Tissues of the Neck in the Sub-Occipital Area: An Unusual Site of Hydatid Cyst. JSM Clin Cytol Pathol 3: 3.

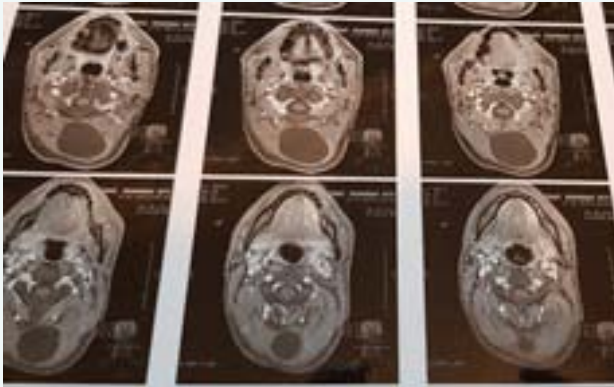


Figure 1 MRI of neck (T1 weighted, axial view) showing cystic lesion the in sub-occipital area base of skull.

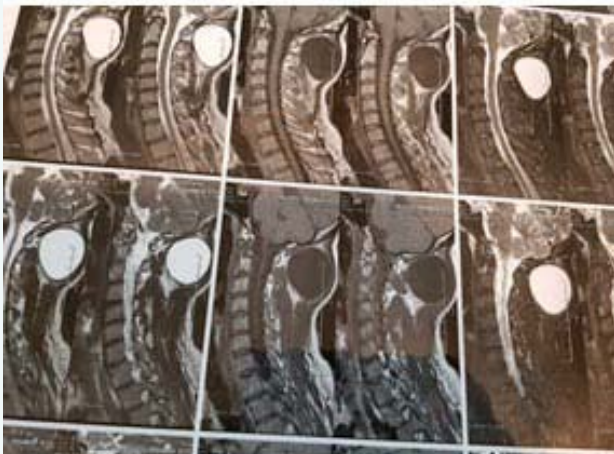


Figure 2 MRI of neck (T2 weighted, axial view) showing cystic lesion in the neck just sub-occipital area.




Figure 3 Showing intraoperative aspiration of cystic lesion fluid.

4). 30CC hypertonic saline was injected in the ruminant cavity. After 10 minuet cyst was opened, a white laminated membranes was exposed and removed intraoperative with presentation of laminated membrane (Figure 4), our diagnosis was hydatid cyst. The cavity was irrigated with providing-idon and was closed with a external drainage. Histopathological examination confirmed the diagnosis of the hydatid cyst. Serological tests were negative for

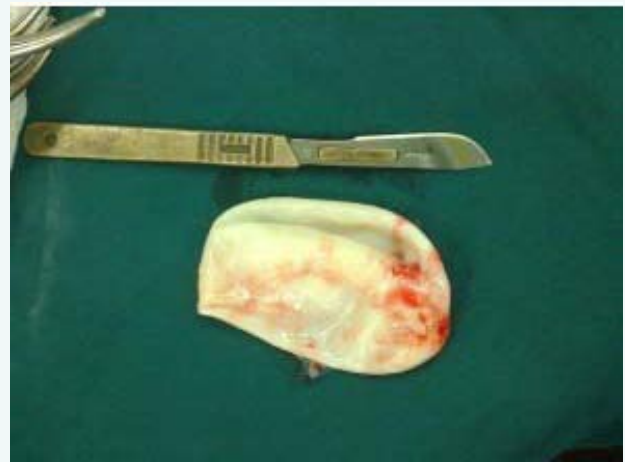

Figure 5 Showing Laminated membrane of cystic lesion, post-operative.

the Echinococcal antigens. No pathology was seen on abdominal and other organs in the CT-scan and USG. The patient was started on an oral albendazole (800mg/daily) treatment for 28 days with 14 day interval in three periods. On follow-up, no recurrence was observed.

Discussion

Hydatid disease is caused by the larval tapeworm of the genus *Echinococcus granulosus*, *E. multilocularis*. *E. granulosus* is the most common cause of hydatid disease [6]. The liver (50-70%) and lung (20-30%) are the most common organs which involve but may be found in any other organ of the body, including brain, heart and bones and adrenal gland (<10%) [7]. It can also affect the kidney, ureter, spleen, uterus, Fallopian tube, mesentery, pancreas, diaphragm and muscles and subcutaneous [8]. Muscular hydatid cysts may be primary, but may also occur secondarily when cysts spread from other areas, either spontaneously or after previous operations for hydatidosis in other regions of the body [8,9]. Hydatid cysts in soft tissues are an unusual presentation of hydatidosis [8]. Primary intramuscular hydatidosis is rare because the intramuscular growth of cysts is hindered by the muscle's contractility, and by the lactic acid in the muscle. Parasitic cysts tend to grow around the muscles of the neck, trunk and roots of the limbs, perhaps because there is greater vascularization and less muscular activity in these regions [2,8]. They develop very slowly and act as space-occupying lesions, producing symptoms related to pressure on the surrounding tissues [5]. Other possible primary locations of the disease must be excluded by careful clinical and radiological examination of the patient, and these examinations must form the basis of the diagnosis. In particular, MRI images may identify various patterns of intramuscular hydatidosis such as its peripheral rim, peripheral edema, peripheral enhancement with gadolinium and multilocular cystic lesion (daughter cysts) [2,3,8]. In our case we used U&S and MRI for diagnosis. Percutaneous needle or open biopsy in this solid and cystic lesion risk for spreading must be avoided [1,2]. Echinococcosis should be always suspected in



differential diagnosis of cystic lesions in soft tissue until proven otherwise. Once the diagnosis is established, the surgeon should consider performing a radically [1,2,8].

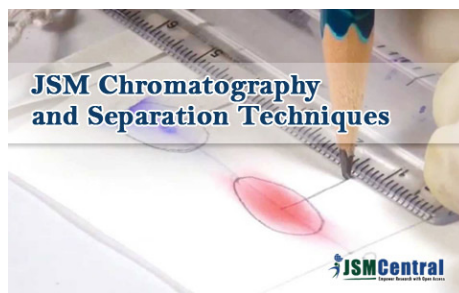
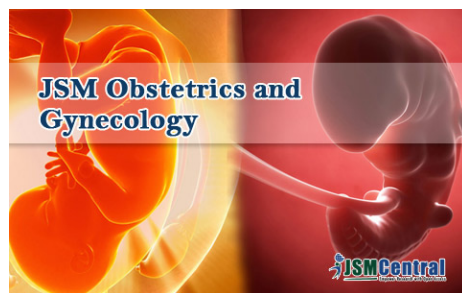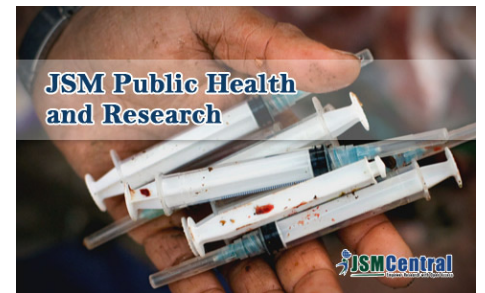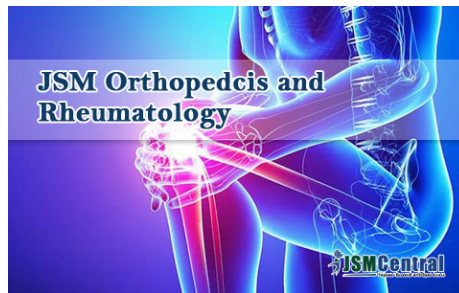
The treatment of choice is complete surgical excision of the cyst mass and thorough irrigation of the surrounding soft tissues with hypertonic saline to prevent recurrence [5,10]. Before the surrounding of cyst should de walling of with hypertonic saline solution. Administration of benzimidazole derivatives (albendazol) preoperatively and after surgery is advocated by some authors [2,8]. In this case we use albendazole (800mg/daily) after surgery. The patient must be kept under clinical evaluation after surgery, for recurrence. Once the diagnosis is established, the surgeon should consider performing a radical procedure aiming in minimizing the possibility of a recurrence. The patient must be kept under clinical evaluation after surgery, for recurrence.

Conclusion

In regions where hydatid disease is endemic, Echinococcosis should be always suspected in differential diagnosis of cystic lesions in soft tissue until proven otherwise. The best treatment is the total excision of the cyst with an intact wall.

References

1. Mohammad Sadegh Eamaeili Delshad, Manouchehr Aghajanzadeh, Hossein Hemmati, Siamakrimaz, Reza Shojaee. Complicated primary Hydatid Cyst in brachioradialis An extremely unusual site. MRJMMS. 2016; 4: 76-78.
2. Manoucheher Aghajanzadeh, Mehdi Karimian, Zahra Sadat Segatoleslami, Shirin Manshori, Rassol Hassanzadeh, Tahereh Marasi. Primary Isolated Hydatid Cyst in Trapezes Muscle: A Extremely Rare Site. 2017; 5: 1-3.
3. Reem Khalifa, Firas Nasser, Ahmed Elsetouhy, Ismail Farag. Case report: Hydatid cyst of the neck. A case report and literature review. Egypt J Ear Nose Throat Allied Sci. 2016; 17: 103-105.
4. Metanat M, Sharifi-mood B, Sandoghi M, Alavi-Naini R. Osseous hydatid disease. Iran J Parasitol. 2008; 3: 60-64.
5. Akal M, Kara M. Primary hydatid cyst of the posterior cervical triangle. J Laryngol Otol. 2002; 116: 153-155.
6. Katilmis H, Ozturkcan S, Ozdemir I, Adadan I. Guvenc, Ozturan S. Primary hydatid cyst of the neck. Am J Otolaryngol. 2007; 28: 205-207.
7. Goyal P, Ghosh S, Sehgal S, Panda I, Kumar A, Singh S. Primary Multilocular Hydatid Cyst of Neck with Unique Presentation: A Rare Case Report and Literature Review. Head Neck Pathol. 2014; 8: 334-338.
8. Manouchehr Aghajanzadeh, Omid Mosafayi, Babak Karimi, Hossein Torabi, Mostafa Ziabari, Mahdi Pursafar. Isolatedextra Hepatic and Extra Pulmonary Hydatid Cyst: Report of 33 Rare cases. Ann Clin Pathol. 2018; 6: 1129.
9. Combalia A, Sastre-Solsona S. Hydatid cyst of gluteus muscle. Two cases. Review of the literature. Joint Bone Spine. 2005; 72: 430-432.
10. Sultana N, Hashim TK, Jan SY, Khan Z, Malik T, Shah W. Primary cervical hydatid cyst: a rare occurrence. Diagn Pathol. 2012; 7: 157.



Our motto is to advance scientific excellence by promoting open access. We are committed in the widest possible dissemination of research and uplift future innovation



Submit Manuscript