

A Non-Contrast Computed Tomography and Intravenous Urography Interrogation in Patients with Renal Colic at Hospitals

Amgad Alrwaili*

Department of Diagnostic Imaging, Health Affairs Hospital in the Northern Region, Saudi Arabia

Article Information

Received date: Apr 09, 2018

Accepted date: May 11, 2018

Published date: May 17, 2018

*Corresponding author

Amgad Alrwaili, Department of Diagnostic Imaging, Health Affairs Hospital in the Northern Region, Saudi Arabia, Tel: 00966508127727; Email: analrwaili@moh.gov.sa

Distributed under Creative Commons CC-BY 4.0

Abstract

Intravenous Urography (IVU) has been used in emergency departments for the evaluation of patients with acute renal and urinary tract colic. A non-contrast computed tomography (NCCT) is rapidly becoming the preferred imaging modality for the evaluation of patients with suspected renal colic.

The purpose of this work is to investigate whether NCCT can replace IVU as the primary modality for the evaluation of patients with acute renal colic in radiology departments at four hospitals from the perspective of comprehensive diagnosis of both techniques.

The methods employed in this study monitor and review the radiological investigation records of 520 patients with acute renal calculi who visited four hospitals between April 2016 and March 2017 and analyse the use of IVU and NCCT.

Patients have been adopted based on their radiological examinations records for renal colic in four hospitals. NCCT showed a more comprehensive diagnosis and a short study time, whereas IVU indicated a lower radiation dose and better cost-effectiveness. An intravenous urogram (IVU) showed 81% sensitivity and 89% specificity, while non-contrast computed tomography (NCCT) had sensitivity and specificity of 95% and 97%, respectively.

In conclusion, NCCT is highly sensitive and specific for renal and ureteral calculi but the challenges it faces are that CT examination generates higher radiation doses compared to examination by IVU, even when using a low radiation dose CT protocol.

Introduction

The renal system is the one of the most common organs to be affected by renal calculi. Urolithiasis and renal colic are common conditions affecting up to 15% of the population during their lifetime [1]. The incidence is approximately 122 in 100,000 outpatient visits; recurrence rates of urinary calculi can reach 50% in 10 years [2]. Intravenous Urogram (IVU) has been used for renal colic investigation but it requires an intravenous contrast with inherent potential toxicity [3]. The accuracy of imaging modalities, such as plain radiography (kidney, ureters, bladder (KUB)), IVU, ultrasound (US), and magnetic resonance imaging (MRI) are the most common radiographic models for different procedures. The sensitivity of plain radiography ranges from 45% to 60%, thus providing limited value for the diagnosis of renal stones [4]. US have demonstrated sensitivity as high as 79% but are less useful in obese patients and in those with mid-ureteral calculi [5]. MRI is highly accurate for diagnosing hydronephrosis in patients presenting with renal colic but it requires conscious sedation, particularly for child patients, which entails a protracted procedure as well as being a claustrophobic experience, particularly owing to the use of a long tunnel.

Recently, multi-slice computed tomography has demonstrated a sensitivity and specificity for diagnosing patients with renal colic [6] which has encouraged radiologists to favour using this technique. This is because it offers relative advantages over the other models, especially regarding imaging by IVU. However, it requires high radiation doses.

Materials and Methods

The selected methodology for this study is retrospectively reviewed radiological examinations for 520 patients with renal colic who were referred to the radiology departments of four hospitals between April 2016 and March 2017.

A prospective study is conducted regarding values of NCCT and IVU in detection of renal calculi performed by radiologists in these 4 hospitals. Probing of the renal stone exposed by conventional X-ray and CT scans for a specific number of cases was done in each hospital.

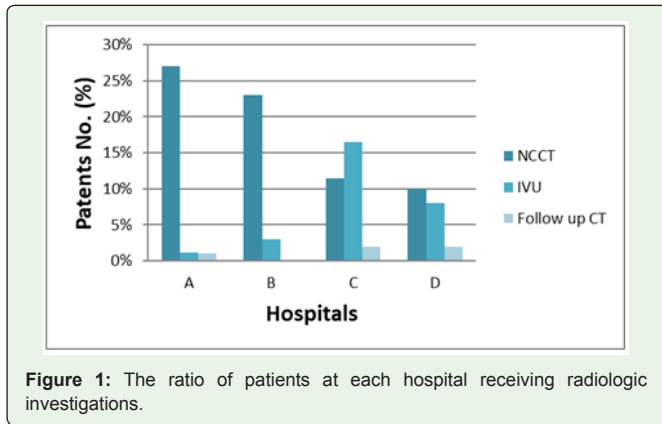


Figure 1: The ratio of patients at each hospital receiving radiologic investigations.

IVU was taken in a standard fashion with 80-100 mL of non-ionic contrast medium. NCCT was executed using multi-slice CT scanners. The anatomic and collimation region between the twelfth thoracic vertebral region and symphysis pubis was exposed. CT scans were taken with 3-mm collimation on a pitch of 1.5 and no contrast medium was given. Statistical graphs were created using Microsoft Excel ver. 10 (Microsoft Office Inc., USA). There was a change in the proportion of patients who underwent imaging studies during the study period. The percentages of patients in the four hospitals have been identified through existing radiological investigations records for each hospital. Cases that have not completed the conditions for the investigation of renal colic were excluded.

Results

The rate of cases in each of the four hospitals for 520 patients have been adopted based on the radiology departments records that were found and that had a radiological examination for renal colic in the period from April 2016 to March 2017.

65% of the patients in hospitals that tend not to use NCCT scanning for patients with renal colic relied on CT, whereas 35% used IVU.

Table 1: Patient's ratio in (%) diagnosed with renal colic in the 4 hospitals.

1.a Renal system	
Renal collecting system diagnosis	40.20%
Ureter stone diagnosis	39.70%
Urinary bladder	20.10%
1.b Radiologic techniques	
NCCT	83%
IVU	17%

IVU: Intravenous Urography; NCCT: Non-Contrast Computed Tomography

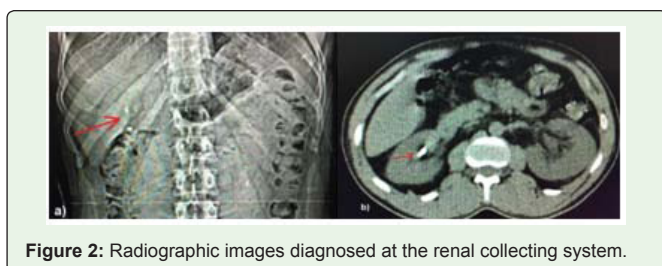


Figure 2: Radiographic images diagnosed at the renal collecting system.

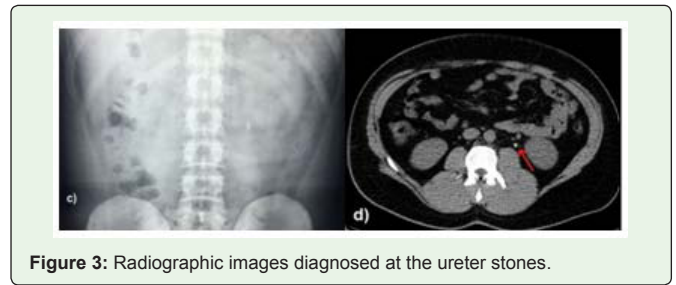


Figure 3: Radiographic images diagnosed at the ureter stones.

The mean age of the patients was 20.5 ± 50.10 years. Of the 520 patients, 74.9% were men. They visited radiology departments for renal colic investigation at the four hospitals: 30.8% of the patients attended A-Hospital, (300 beds); 25.9% attended B-Hospital, (150 beds); 24.5% attended C-Hospital 100 beds; and 18.8% attended D-Hospital, (200 beds).

Of the patients who attended A-hospital, 145 were evaluated by NCCT, IVU was performed for 6 patients (0.5%) and 4 patients were confirmed by conventional CT. In B-hospital, a total of 135 patients were evaluated immediately by NCCT, with 16 patients relying on IVU. At C-hospital, 60 patients were assessed by NCCT. A further 68 patients were assessed by conventional X-ray (KUB) and then followed by IVU; with 2% of them being confirmed by conventional CT. At D-hospital, 96 patients were evaluated by IVU and 80 patients were referred for conventional CT for confirmation (see Figure 1).

NCCT and IVU were performed to diagnose renal stones at the renal collecting system, ureter and urinary bladder from April 2016 to March 2017 in all hospitals. For both techniques, radiographic images were selected for each anatomical location. 40.2% were diagnosed at the renal collecting system (Figure 2), 39.7% were diagnosed with ureter stones (Figure 3), and 20.1% for urinary bladder (Figure 4).

The proportion of patients diagnosed by NCCT at all locations increased significantly to 83%, whereas just 17% of patients had IVU (Table 1).

The reliability of diagnosis (no need confirmation), cost, study time and radiation exposure of NCCT and IVU are illustrated in Table 2.

Table 2: Comparison of comprehensive diagnosis, cost, study time and radiation exposure among imaging modalities.

Techniques	IVP	NCCT
The comprehensive diagnosis	Low	High
Cost (US.D)	\$120 - \$280	\$300 - \$500
Study time (Min)	120-180 minutes	About 7 minutes
Radiation exposure (mSv)	0.5 in each film	About 3.5

mSv: millisievert

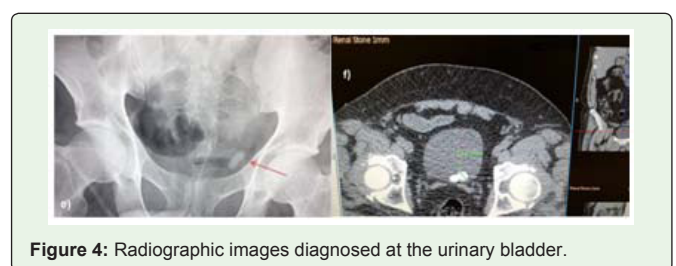


Figure 4: Radiographic images diagnosed at the urinary bladder.

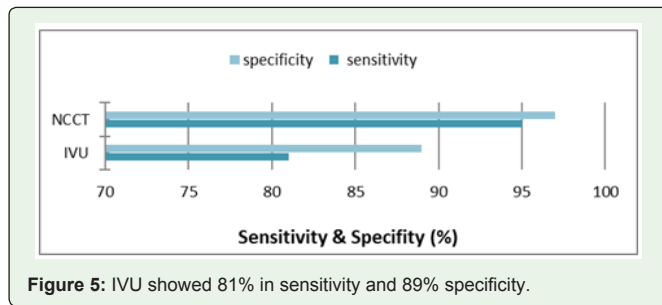


Figure 5: IVU showed 81% in sensitivity and 89% specificity.

Whereas NCCT showed a more comprehensive diagnosis in a short study time, IVU required a lower radiation dose and offered better cost-effectiveness. An intravenous urogram, IVU showed 81% in sensitivity and 89% specificity (Figure 5). In the case of NCCT, its sensitivity and specificity were 95% and 97% respectively.

Discussion

This study has demonstrated that there was a significant increase in the use of NCCT for patients with renal colic in the 4 hospitals during the period from March 2016 to April 2017. Previous studies have demonstrated that CT has been introduced to evaluate renal colic and it has proved to be an effective modality for the diagnosis of urinary calculi [6,7].

In this work, the use of alternative imaging modalities (i.e. CT or IVU) were monitored, thereby demonstrating that CT use significantly increased and IVU use decreased in most 4 hospitals during the period of study.

In three hospitals (A, B and D) between 2016 and 2017, fewer IVU procedures were ordered for patients with renal colic than were ordered to follow-up.

Although the number of IVU procedures increased significantly at C-hospital, it would be thought that this was incongruous because follow-up CT was performed in just 5% of cases.

Compared with IVU, the reported sensitivity of NCCT for evaluating patients with suspected renal calculi was 95% and its specificity was 97% [8,9]. NCCT showed higher sensitivity and specificity than did IVU in this respect because all urinary tract calculi could be identified by NCCT [10]. Moreover, NCCT could evaluate the severity of the ureter obstructions [11].

The advantage of NCCT over IVU is the rapid image acquisition time, advanced image quality, and the fact that it can be performed without requiring a contrast medium, thereby avoiding any risk of contrast-induced adverse reactions, which can occur in patients who undergo IVU [12].

IVU was the traditional examination for the assessment of urinary stone disease and it does provide physiological information relating to the degree of obstruction. However, it could give false-positive results due to phleboliths adjacent to the ureter. In some cases, NCCT may be needed to detect it in the ureter. Urinary calculi might be un-diagnosable with IVU in patients who had urographic findings of unilateral ureteral obstruction due to small stone size or a lack of stone radiolucency [13].

The drawbacks with IVU are that patients with renal colic associated with renal insufficiency have contraindications for IVU owing to the potential nephrotoxicity of the contrast material. IVU is less sensitive than CT, especially for small or non-obstructing stones [11]. Patients with urinary calculi are at increased risk of excessive radiation exposure due to the repetition of radiographic examinations [14,15]. There is also concern about an increased cancer risk resulting from the radiation exposure associated with repeatable medical imaging [16]. The disadvantage with NCCT is the high radiation exposure [17]. Although examination costs vary among hospitals; many of them charge less for CT scans that are performed without a contrast medium because the use of NCCT eliminates the cost of the contrast medium. Conversely, the cost of CT equipment is higher than that required for IVU but the room time for CT is less than that for IVU [18].

Conclusion

Most radiologists in four hospitals tend to be more comfortable with NCCT investigation for renal colic cases. NCCT when compared with IVU is a relatively quick test to perform for the evaluation of patients with suspected renal colic. NCCT is highly sensitive and specific for renal and ureteral calculi. More importantly, it allows visualisation of alternative pathology.

In addition, secondary signs are seen that assist with determining obstructions and are helpful if no stone is visualised as phleboliths, which can simulate a stone, are rarely seen in young adults. It is believed that NCCT allows for rapid triage and localisation of kidney stones. In spite of the advantages offered by this technique, it requires higher radiation doses than IVU. In contrast, IVU provides more information with regards to the function of the urinary system. This study may contribute to the issue of the privatization of radiology departments in hospitals of the Ministry of Health.

References

1. Parmar MS. "Clinical review, Kidney stones". *BMJ*. 2004; 328: 1420.
2. Stroup SP, Auge BK. Important Military Role for Medical Expulsion, Therapy of Urolithiasis. *Mil Med*. 2008; 173: 393-398.
3. Saljoughian M. Intravenous Radiocontrast Media: A Review of Allergic Reactions. *US Pharm*. 2012; 37: 14-16.
4. Moloney F, Murphy KP, Twomey M, O'Connor OJ, Maher MM. Haematuria: An Imaging Guide. *Advances in Urology*. 2014; 414125: 9.
5. Datta SN, Allen GM, Evans R, Vaughton KC, Lucas MG. Urinary tract ultrasonography in the evaluation of haematuria. *Ann R Coll Surg Engl*. 2002; 84: 203-205.
6. Worster A, Preyra I, Weaver B, Haines T. "The accuracy of noncontrast helical computed tomography versus intravenous pyelography in the diagnosis of suspected acute urolithiasis: a meta-analysis". *Ann Emerg Med*. 2002; 40: 280-286.
7. Wang LJ, Wong YC, Huang CC, Wu CH, Hung SC, Chen HW. "Multidetector computerized tomography urography is more accurate than excretory urography for diagnosing transitional cell carcinoma of the upper urinary tract in adults with hematuria". *J Urol*. 2010; 183: 48-55.
8. Cowan NC, Turney BW, Taylor NJ, McCarthy CL, Crew JP. "Multidetector computed tomography urography for diagnosing upper urinary tract urothelial tumour". *BJU Int*. 2007; 99: 1363-1370.

9. Tack D, Sourtzis S, Delpierre I, de Maertelaer V, Gevenois PA. "Low-dose unenhanced multidetector CT of patients with suspected renal colic". *AJR Am J Roentgenol.* 2003; 180: 305-311.
10. Maher MM, Kalra MK, Rizzo S, Mueller PR, Saini S. Multidetector CT urography in imaging of the urinary tract in patients with hematuria. *Korean J Radiol.* 2004; 5: 1-10.
11. Kawashima A, Glockner JF, King BF. CT urography and MR urography. *Radiol Clin North Am.* 2003; 41: 945-961.
12. Maddox T. Adverse Reactions to Contrast Material: Recognition, Prevention and Treatment. *American Family Physician.* 2002; 66: 7.
13. Rao S. *Acute Obstructive Uropathy Imaging.* 2017.
14. Van DerMolen AJ, Cowan NC, Mueller-Lisse UG, Nolte-Ernsting CC, Takahashi S, Cohan RH, et al. CT urography definition, indications and techniques. A guideline for clinical practice. *Eur Radiol.* 2008; 18: 4-17.
15. Katz SI, Saluja S, Brink JA, Forman HP. Radiation dose associated with unenhanced CT for suspected renal colic: impact of repetitive studies. *AJR Am J Roentgenol.* 2006; 186: 1120-1124.
16. Sodickson A, Baeyens PF, Andriole KP, Prevedello LM, Nawfel RD, Hanson R, et al. Recurrent CT, cumulative radiation exposure, and associated radiation-induced cancer risks from CT of adults. *Radiology.* 2009; 251: 175-184.
17. Fazel R, Krumholz HM, Wang Y, Ross JS, Chen J, Ting HH, et al. Exposure to low-dose ionizing radiation from medical imaging procedures. *N Engl J Med.* 2009; 361: 849-857.
18. Eikefjord E, Askildsen JE, Rørvik J. Cost-Effectiveness Analysis of Intravenous Urography (IVU) and Unenhanced Multidetector Computed Tomography (MDCT) for Initial Investigation of Suspected Acute Ureterolithiasis. *Acta radiologica.* 2008; 49: 222-229.