

Successful Treatment of Rhinocerebral Mucormycosis with Early and Prolonged Antifungal Therapy- A Case Report

Gayathiri GR¹, Saraswathi T², Vijayakumar A³ and Arulselvan V^{4*}

¹Clinical Pharmacist, Kovai Medical Centre and Hospital, India

²Neuro Intensive Care Unit, Kovai Medical Centre and Hospital, India

³Manager Pharmacy Services, Kovai Medical Centre and Hospital, India

⁴Department of Neurology, Kovai Medical Centre and Hospital, India

Article Information

Received date: Jul 02, 2018

Accepted date: Aug 01, 2018

Published date: Aug 06, 2018

*Corresponding author

Arulselvan V, Consultant Neurologist,
Kovai Medical Centre and Hospital,
Coimbatore -641014, Tamilnadu, India,
Tel: +91 - 9489168862;
Email: arul441@hotmail.com

Distributed under Creative Commons
CC-BY 4.0

Keywords Mucormycosis; Liposomal
amphotericin B; *Rhizopus*; Posaconazole

Abstract

Mucormycosis is a serious and deadly fungal infection caused by filamentous fungi of mucoraceae family usually by *Mucor* or *Rhizopus* species occurs in patients with weakened immune system and uncontrolled diabetes mellitus. Rhino-orbito cerebral form presents with a fever, headache, rhinorrhea, formation of black necrotic intranasal or intra oral masses progress to orbital cellulitis. Filamentous mucorales prefer low oxygen, high glucose, acidic medium and increased iron levels. Poor glycemic control decrease the ability of neutrophils to phagocytize and also modify the ability of macrophages, hence poorly controlled diabetes mellitus is a risk factor for invasive mucormycosis. Early histopathological examination of the affected tissue with fungal culture confirms the diagnosis. Aggressive treatment for achieving euglycemia and correcting acid status is the cornerstone of therapy. Treatment of rhinocerebral mucormycosis involves surgical debridement with prolonged systemic antifungal therapy and control of glycemic status.

Case Report

A 31 year old male patient recently diagnosed type 2 diabetes presented with headache, vomiting, epigastric pain and right eye swelling. On examination he was severely dehydrated, tachypneic, tachycardic and he had mild right eye swelling. His BP was 140/80 mmHg. His random blood sugar was 461 mg/dl, had severe metabolic acidosis on ABG analysis (pH -7.07, HCO₃-1.9, PCO₂-6.8, PO₂-139.3 and lactate -1.4). He was resuscitated with IV fluids and insulin infusion. He was intubated and ventilated for respiratory distress. After resuscitation his Glasgow Coma Scale (GCS) was E₃V₁M₆. MRI brain was done which showed orbital cellulitis and acute infarct in basifrontal region with central retinal artery occlusion (Figure 1).

KOH swab was done from right eye discharge which showed the presence of fungal elements. He was diagnosed to have rhino-orbital mucormycosis. He was then started on intravenous Liposomal Amphotericin B (400 mg/ day) 6.6 mg/kg/day.

Patient underwent Functional Endoscopic Sinus Surgery (FESS), right radical maxillectomy, right frontal abscess drainage and right eye exentreatment. Histopathological examination of the brain abscess wall was done and confirmed invasive zygomycosis and CNS pus grown *Klebsiella pneumonia* with a resistant strain of possible carbapenemase producer. He was treated with intravenous fosfomycin and intrathecal colistin. His glycemic status was controlled with IV insulin. Patient developed severe hypokalemia and hypomagnesemia following amphotericin therapy which was intensively corrected with intravenous and oral supplements.

After 10 days, follow up MRI showed acute infarct in the right parietal lobe, suggestive of cerebritis. Patient GCS was improving; renal and liver parameters were monitored thrice weekly and were normal throughout the therapy. On 3rd week he had hyperthermia, follow-up CT scan brain showed bi-frontal abscess (Figure 2) for which abscess drainage was done again and continued with IV Liposomal Amphotericin B. His GCS improved E₄V₁M₆, he was weaned from ventilator.

Follow up CT brain after 10 days showed no further abscess formation (Figure 3). He was afebrile throughout. IV Liposomal Amphotericin B was switched over to syrup Posaconazole 10 mg/kg/day. He was discharged after 40 days of hospital stay and he was advised to continue oral posaconazole and insulin therapy. He was reviewed every 15 days at Outpatient basis. His neurological status was improved and he was de-cannulated after 2 weeks. He was advised to continue oral posaconazole for 6 months.

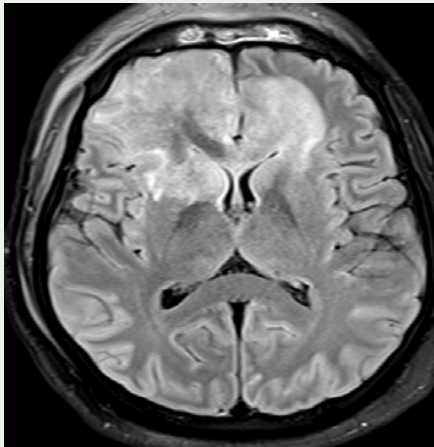


Figure 1: MRI Brain - Orbital cellulitis and basifrontal acute infarct.

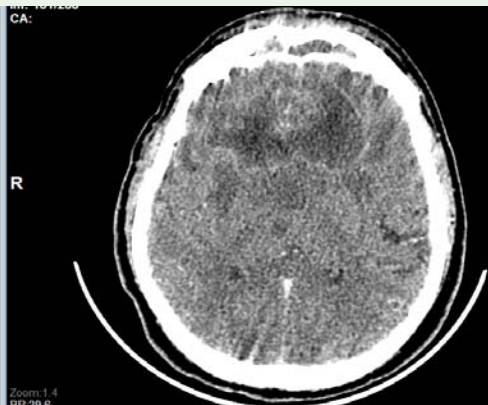


Figure 2: CT Scan Brain - bifrontal abscess.

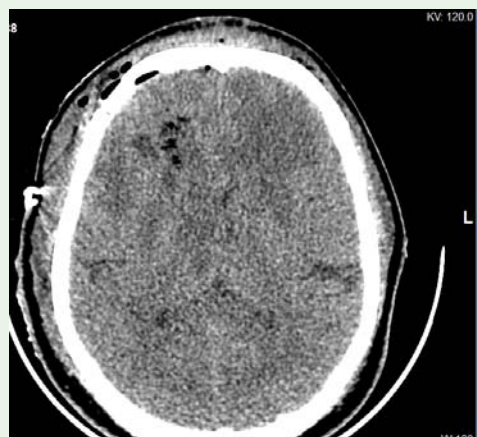

Figure 3: Follow-up CT scan brain 10 days (Before surgery) after abscess drainage.

Discussion

Rhino-orbito cerebral mucormycosis begins with invasion of fungus into the nasal or oral mucosa [1,2]. Infection spreads by

direct extension into paranasal sinuses and provokes tissue necrosis, so that fungus can easily invade blood vessel leading to thrombosis and ischemia and enters CNS [1,2]. Fungal growth prefers low oxygen, iron overload, acidosis and hyperglycemic conditions for its growth, hence patients with predisposing factors like poorly controlled diabetes mellitus, immunosuppressed, hematological malignancies are affected [3,4]. Mortality rate is highly associated with delayed diagnosis and underlying medical co-morbidity [2]. Diagnosis is confirmed by the histopathological examination of fungi in the affected tissue. Guideline for treating rhino orbito cerebral mucormycosis is usually repeated aggressive surgical intervention often involving orbital exenteration and medical management with anti-fungal agent like Amphotericin B remains the mainstay [3,5]. Liposomal Amphotericin B is significantly less nephrotoxic and has significant CNS penetration at a dose of 5-7.5 mg/kg/day. For CNS mucormycosis higher doses of 10 mg/kg/day can also be given [4,6]. Patient's underlying condition should be corrected and IV anti-fungal can be changed to oral Posaconazole 20 mg/kg/day, which can reduce the fungal load in the brain effectively [7]. Patient's glycemic status and acid-base status should be corrected aggressively which reduces the multiplication of fungus [8,9].

Therapy with anti-fungal drug should be continued until 1) Resolution of signs and symptoms of infection, 2) stabilization of radiographic findings of the disease on serial imaging, 3) Correction of underlying causes of infection. Early diagnosis and aggressive treatment can reduce the mortality and improves neurological outcome.

Acknowledgment

The authors are thankful to Dr. Nalla G Palaniswami, Chairman and Managing Director of Kovai Medical Center and Hospital, Coimbatore, Dr. Thavamani D Palaniswami, Trustee, Kovai Medical Center Research Cancer and Educational Trust and Dr. Arun N Palaniswami, Director of Quality Control, Kovai Medical Center and Hospital, Coimbatore for providing necessary facilities and continuous encouragement

References

1. Mohammadi R, Nazeri M. A successful treatment of rhinocerebral mucormycosis due to *Rhizopus oryzae*. *J Res Med Sci*. 2014; 19: 72-74.
2. Dokmetas H S, Canbay E. Diabetic ketoacidosis and rhino-orbital mucormycosis. *Diabetes Res Clin Pract*. 2002; 57:139-42.
3. Vilalta V, Munuera J. Rhino-cerebral mucormycosis: Improving the prognosis of life-threatening disease. *J Infect Dis Ther*. 2014; 2: 1-3.
4. Kulendra K, Habibi M. Use of posaconazole in the treatment of infective rhinocerebral mucormycosis. *J Laryngo Otol*. 2010; 124:1314-317.
5. Peterson L, Wang M. Rhinocerebral mucormycosis: Evolution of the disease and treatment options. *Laryngoscope*. 1997; 107: 855-862.
6. Spellberg B, Walsh TJ. Recent advances in the management of mucormycosis: from bench to bedside. *Clin Infect Dis*. 2009; 48: 1743-1751.
7. Rodriguez U, Serena C. Posaconazole combined with amphotericin B, an effective therapy for a murine disseminated infection caused by *Rhizopus oryzae*. *Antimicrob Agents Chemother*. 2008; 52: 3786-3788.
8. Harrill W C, Stewart M. Chronic rhinocerebral mucormycosis. *Laryngoscope*. 1996; 106:1292-1297.
9. SM Oladeji, YB Amusa. Rhinocerebral mucormycosis in a diabetic - case report. *J West Afr Coll Surg*. 2013; 3: 93-101.