

Chondromyxoid Fibroma of the Calcaneus: A Case Report and Literature Review

Mohamed Amine Azami^{1*}, Othman Lahbali¹, Iliass El alami², M Bassir³, M Mahfoud³, MS Berrada³, F Zouidia¹ and N Mahassini¹

¹Department of pathology, University Hospital Ibn Sina, Mohammed V University in Rabat, Morocco

²Department of oncology, Mohamed V military hospital, Mohammed V University in Rabat, Morocco

³Department of Orthopedics, University Hospital Ibn Sina, Mohammed V University in Rabat, Morocco

Article Information

Received date: Jan 19, 2017

Accepted date: Feb 01, 2017

Published date: Feb 03, 2017

*Corresponding author

Mohamed Amine Azami, Department of pathology, University Hospital Ibn Sina, Mohammed V University in Rabat, Morocco, Tel: +212662103334; Email: dr.azamiamine.aa@gmail.com

Distributed under Creative Commons CC-BY 4.0

Keywords Calcaneus; Cartilaginous tumor; Chondromyxoid Fibroma

Abstract

Chondromyxoid fibroma is a rare benign primary bone tumor composed of immature myxoid mesenchymal and cartilaginous tissue. It has a predilection for the metaphyseal area of long tubular bones of lower extremities in young patients. Its occurrence in calcaneus is very rare and few cases of calcaneal involvement have been reported in literature. This mass can mimic other benign and malignant bone tumors owing to its variable histologic features. A case report is demonstrated, discussing the problems of misdiagnosis. A brief review of the literature is presented.

Introduction

Chondromyxoid Fibroma (CMF) is a rare benign primary bone tumor composed of immature myxoid mesenchymal and cartilaginous tissue. It has a predilection for the metaphyseal area of long tubular bones of lower extremities in young patients [1].

Pathologic examination is difficult but can be used to differentiate this lesion from more serious conditions. Histologically, chondromyxoid fibroma appears as an unusual mixture of fibroid, chondroid, and myxoid tissues [2].

The originality of this case lies in the rarity of this type of bone tumor, calcaneus location that is even more rare and differential diagnostic problem which arises.

Case Report

A 22-year-old man presented with chronic left ankle pain of 2 years duration. He related that her pain was aching and throbbing in nature and aggravated by movement such as walking and standing and the toe off portion of gait. Associated symptoms included decreased mobility, limping, swelling, and tenderness on examination. Previous treatment included hardware removal from the ankle, non-steroidal anti-inflammatory drugs, oral and injectable steroids, and immobilization without success. The physical examination revealed an antalgic gait with mild localized edema to the left lateral ankle and lateral calcaneus. Radiographic evaluation of the left foot and ankle revealed a well circumscribed, geographic lesion in the body of the calcaneus measuring 4 x 3.5 cm, without calcification (Figure 1). A computed tomography scan was performed to evaluate the cortex of the

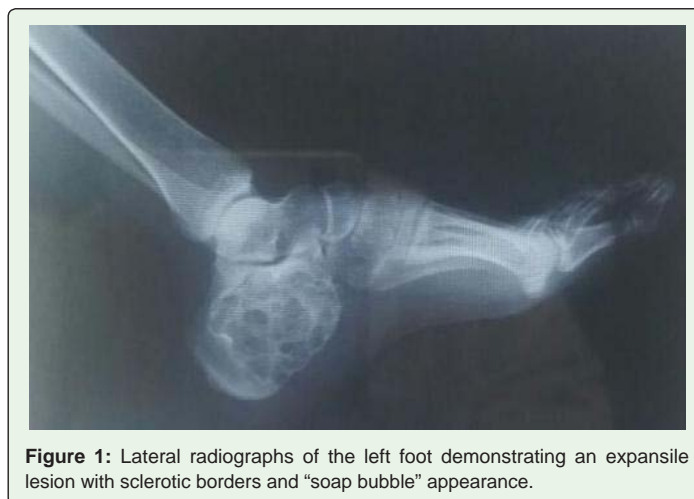

Figure 1: Lateral radiographs of the left foot demonstrating an expansile lesion with sclerotic borders and “soap bubble” appearance.



Figure 2: Gross appearance of CMF, fibro-gelatinous substance with pieces of cartilaginous material.

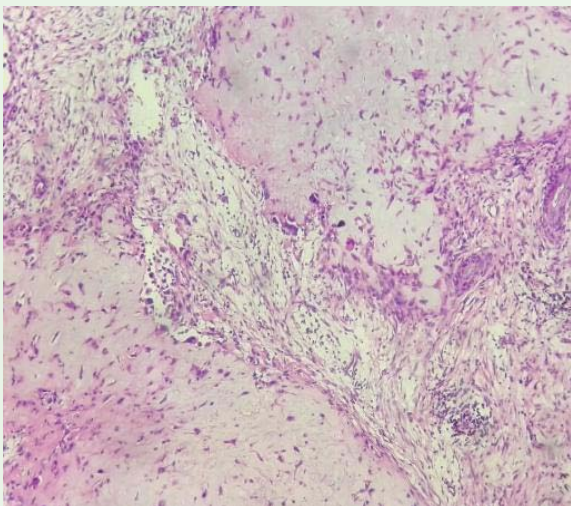


Figure 3: Lobules of cartilage separated by fibrocellular tissue (H&E x 100).

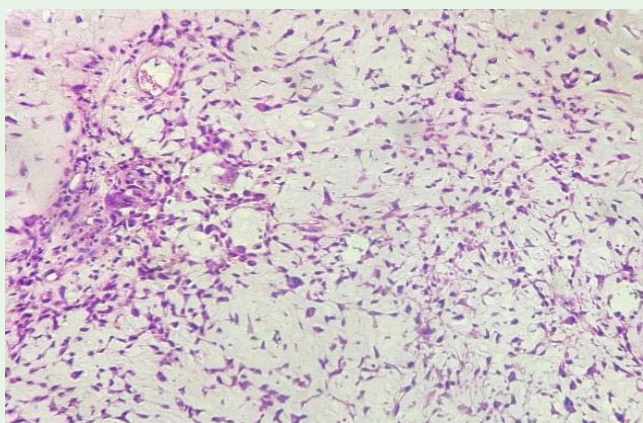


Figure 4: Myxoid background with a mixed of variable proportions of chondroid cells, stellate cells and multinucleated giant cells (H&E x 200).

lateral calcaneus. This revealed a lytic lesion with well-circumscribed borders and an appearance consistent with a unicameral bone cyst.

The MRI was not done because it is very expensive for the patient.

The patient underwent the informed consent process for surgical intervention and definitive surgical excision of the lesion was planned.

Under general anesthesia, a surgery was performed to remove the tumor. A curettage and autogenously bone graft was realized to close the osseous defect in the involved calcaneus.

Intra-operatively, we noticed the characteristic gross appearance of the lesion, which was composed of white fibro-gelatinous substance with pieces of cartilaginous material (Figure 2).

The pathologic examination demonstrated a lesion composed of collagenous matrix with stellate to spindle-shaped cells with bland nuclear features. Features of fibrous, chondroid, and myxoid stroma were visualized. Hypercellular areas were present at the periphery of the chondromyxoid stroma (Figure 3 and Figure 4).

We did not have any recurrence in our patient during the follow-up period. He was able to return to regular activity free of symptoms, approximately 12 months following surgery.

Discussion

Chondromyxoid fibroma (CMF) is a benign, locally aggressive tumor of cartilaginous origin and accounts for less than 0.5% of all bone tumors [3]. In 1948, the tumor was first described by Jaffe and Lichtenstein as a lesion derived from cartilage-forming tissue and composed of various proportions of chondroid, fibrous, and myxoid tissues [4].

CMF affects the long tubular bones of the lower extremity in 75% of cases, with 40% involving the knee and 17% to 20% reported in the foot, making it the second most frequent location [5]. Occurrence of CMF in the calcaneus is very rare and few cases of calcaneal involvement have been reported in literature [6-8].

Seventy percent of cases present within the second to third decade of life, with a second peak incidence occurring within the fifth to seventh decades [9,10].

The typical clinical presentation of chondromyxoid fibroma is pain associated with a palpable mass or area of swelling that is extremely tender on palpation. The periosteum usually remains intact except in rare cases of pathologic fractures [11].

On some occasions, the tumor may be asymptomatic and may present as an incidental finding on radiographic examination [12]. The clinical presentation in our patient is similar to what is published in literature.

The diagnosis of CMF is usually made in conjunction with findings from plain radiographs, MRI, computed tomography, or nuclear bone scans.

The radiographic appearance of CMF varies; however the radiological findings of CMF in calcaneus are eccentric, lytic lesion with thin sclerotic rim and trabeculations in large cysts [13].

MRI can be used to characterize the tumor and assess the tumor extent and is the modality of choice for preoperative delineation of tumor extension. The appearance of CMF on MRI is similar to that of other cartilage-based lesions [14].

The radiographic findings in our cases were compatible with classic descriptions.

Diagnosis of CMF basically depends on its characteristic histological appearance. Grossly, CMF appears as a gray or white multiloculated mass that might exhibit a blue or tan tint. There is a resemblance to cartilage, and the margins of the lesion are sharply demarcated from the scalloped rim of bone [15].

Histologically, CMF demonstrates lobules composed of variable proportions of chondroid, myxoid, and fibroid tissue [15-18]. The chondroid tissues contain chondroblasts and chondrocytes within different stages of differentiation and maturation [15]. Spindle- to stellate-shaped cells are numerous in the periphery of the lobules within the myxoid and chondroid tissues [16]. Fibrous tissues separate the chondroid and myxoid regions and contain varying amounts of interstitial collagen fibers, fibroblasts, histiocytes, hemosiderin pigments, and multinucleated giant cells [15].

The differential diagnosis of CMF includes chondroblastoma, chondrosarcoma, enchondroma, and aneurysmal bone cyst, but it is the salient histological features that distinguish these lesions [18].

Treatment of CMF typically involves surgical curettage with a bone graft or en bloc resection with a bone graft for larger lesions [15,16]. Some cases of CMF can be cured by simple curettage but the incidence of recurrence after this treatment is relatively high, varying from 12.5 to 25% in different reports and it is not recommended [12].

Radiation therapy has no place in the treatment of such conditions and has been mentioned only in surgically inaccessible lesions [16,19]. This is because of the risk of malignant transformation, chronic osteomyelitis and radio-necrosis [17].

Conclusion

Chondromyxoid fibroma is an uncommon benign bone neoplasm. It mainly affects the metaphysis of long bones, the proximal tibia being the most common location. Calcaneus location it's very rare and difficult to diagnose because it's often confused with more aggressive tumors and is misdiagnosed many times.

Authors' contributions

All three authors contributed and approved the final version of the manuscript.

References

1. Jamshidi K, Mazhar FN, Yahyazadeh H. Chondromyxoid fibroma of calcaneus. *Foot Ankle Surg.* 2013; 19: 48-52.
2. Mirra JM. *Bone Tumors: Clinical, Radiologic and Pathologic Correlations*, Lea &Febiger, Philadelphia. 1989; 623.
3. Robert K, Heck. *Benign/aggressive tumors of bone*. Campbell's Operative Orthopaedics. Canale ST, Beatty JH (editors): Mosby Elsevier, Philadelphia. 2013; 1: 894.
4. Jaffe HL, Lichtenstein L. Chondromyxoid fibroma of bone; a distinctive benign tumor likely to be mistaken especially for chondrosarcoma. *Arch Pathol (Chic)*. 1948; 541-551.
5. Rahimi A, Beabout JW, Ivins JC, Dahlin DC. Chondromyxoid fibroma: a clinicopathologic study of 76 cases. *Cancer*. 1972; 30: 726-736.
6. Ebrahimzadeh MH, Dallouei SR. Chondromyxoid fibroma of the calcaneus. *J Am Podiatr Med Assoc*. 2007; 97: 223-224.
7. Oommen AT, Madhuri V, Walter NM. Benign tumors and tumor-like lesions of the calcaneum: a study of 12 cases. *Indian J Cancer*. 2009; 46: 234-236.
8. Sharma H, Jane MJ, Reid R. Chondromyxoid fibroma of the foot and ankle: 40 years Scottish bone tumor registry experience. *International Orthopaedics*. 2006; 30: 205-209.
9. Takenaga RK, Frassica FJ, McCarthy EF. Subperiosteal chondromyxoid fibroma: a report of two cases. *Iowa Orthop J*. 2007; 27: 104-107.
10. Wu KK. Chondromyxoid fibroma of the foot bones. *J Foot Ankle Surg*. 1995; 34: 513-519.
11. Wilson AJ, Kyriakos M, Ackerman LV. Chondromyxoid fibroma: radiographic appearance in 38 cases and in a review of the literature. *Radiology*. 1991; 179: 513-518.
12. Schajowicz F, Gallardo H. Chondromyxoid fibroma (fibromyxoid chondroma) of bone. A clinico-pathological study of thirty-two cases. *J Bone Joint Surg Br*. 1971; 53: 198-216.
13. Wilson AJ, Kyriakos M, Ackerman LV. Chondromyxoid fibroma: radiographic appearance in 38 cases and in a review of the literature. *Radiology*. 1991; 179: 513-518.
14. Eric J. Roberts and all: Chondromyxoid Fibroma of the Calcaneus: Two Case Reports and Literature Review. *The Journal of Foot & Ankle Surgery*. 2013; 52: 643-649.
15. Zillmer DA, Dorfman HD. Chondromyxoid fibroma of bone: thirty-six cases with clinicopathologic correlation. *Hum Pathol*. 1989; 20: 952-964.
16. Giudici MA, Moser RP, Kransdorf MJ. Cartilaginous bone tumors. *Radiol Clin North Am*. 1993; 31: 237-259.
17. Lersundi A, Mankin HJ, Mourikis A, Hornicek FJ. Chondromyxoid fibroma: a rarely encountered and puzzling tumor. *Clin Orthop Relat Res*. 2005; 439: 171-175.
18. Damle RP, Suryawanshi KH, Dravid NV, et al. Chondromyxoid fibroma of bone. *JCR*. 2013; 3: 228-231.
19. Armah HB, McGough RL, Goodman MA, Gollin SM, Surti U, Parwani A, et al. Chondromyxoid fibroma of rib with a novel chromosomal translocation: a report of four additional cases at unusual sites. *Diagn Pathol*. 2007; 2: 44.