



# Primary Bilateral Rhabdomyosarcoma of the Breast in a young female. Report of a case with unusual clinical presentation and review of the literature

Emily Alimia\*, Cameron Volpe, Jacob Cunningham, Malina Mohtadi, Victoria DeTrollo, Bishoy Mark Joseph, Nastaran Biriji, and Mohamed Aziz

Department of Pathology, American University of the Caribbean School of Medicine, 1 University Drive at Jordan Road Cupecoy

## Abstract

Cancer of the breast is the most common cancer among women. Rhabdomyosarcoma (RMS) of the breast is a rare sarcoma that is often diagnosed late. Only 5% of breast tumors are of nonepithelial origin, and only 0.2% of RMS originate in the breast.

Optimal treatment of breast rhabdomyosarcoma is not standardized yet. RMS can present a serious diagnostic challenge due to its resemblance to benign tumors of the breast in imaging studies leading to late diagnosis and unfavorable prognosis. Little is known about standard treatment of breast rhabdomyosarcoma. The 5-year survival rate for primary breast rhabdomyosarcoma is about 43%. We present a case of Primary Bilateral Rhabdomyosarcoma of the Breast in a young female with unusual clinical presentation with a review of the literature.

**Keywords:** Rhabdomyosarcoma, Breast, Bilateral, Benign, Malignant; Non-epithelial

## Abbreviation

**RMS:** Rhabdomyosarcoma, **FNA:** Fine needle aspiration, **IHC:** Immunohistochemistry

## Introduction

Rhabdomyosarcoma (RMS) is a rare soft tissue malignancy that is derived from cells that typically form striated muscle tissue. It is the most common soft tissue malignancy in children and adolescents, frequently involving the head, neck, orbital cavity, genitourinary system, and extremities.<sup>2</sup> RMS can be broken down into subclassifications which include embryonal commonly involving the orbit, botryoid RMS commonly involving the bladder and vagina, anaplastic RMS associated with Li-Fraumeni syndrome, and alveolar RMS often involving extremities.<sup>5</sup> In rare instances, RMS can originate from the breast.

Breast masses presenting in adolescent and young adult females are commonly benign such as fibroadenoma and fibrocystic changes. Due to the frequent presence of benign breast tumors, malignant masses may be easily overlooked. An extremely rare form of breast cancer is primary breast

rhabdomyosarcoma, making up only 0.2% of cases. Although the alveolar subtype of RMS typically involves the extremities, it also contributes to the majority of primary breast RMS cases.<sup>7</sup> According to Bayramoglu, only 25 cases of primary breast RMS in the pediatric population have been recorded between the years 1985 and 2017, exemplifying the rarity of this malignancy.<sup>1</sup>

This case discusses primary bilateral RMS of the breast in an 18-year-old female. Due to the rare occurrence of this form of breast cancer, it is often diagnosed late and very little is known on how to effectively treat it. The 5-year survival rate for primary breast RMS is only 43%, making this a critical case report.<sup>10</sup>

## Case Presentation

An 18-year-old female presented to the breast clinic complaining of bilateral breast masses, which she noticed a few months earlier. The patient sought medical attention due to enlargement of the masses. Physical examination revealed no lymphadenopathy and the masses measured 4.2x3.6 (right) & 3.4x2.8 (left). She had no significant medical history or specific risk factors. The patient had no family history of breast cancer. Her father had a history of colon cancer and her mother has a history of atypical endometrial hyperplasia.

An ultrasound was performed, which showed inhomogeneous, hypochoic oval masses with well-defined margins, suggestive of a benign tumor. This was followed by a fine needle aspiration (FNA) and core biopsy from both masses of right and left breasts. There was round, oval and polygonal to elongated cells with occasional dispersed individual cells and many cells containing amphophilic cytoplasm with dense nuclear chromatin and irregular nuclear membranes (**Figure 1A-B-C**). The results were suggestive of a malignant neoplasm with "small blue cell" features, consistent with neuroendocrine tumor with differential diagnosis including lymphoma and sarcoma. A high suspicion of lymphoma rendered a bone marrow biopsy, which revealed

**Submitted:** 03 August, 2021 | **Accepted:** 23 August, 2021 | **Published:** 25 August, 2021

**\*Corresponding author(s):** Alimia Emily, Department of Pathology, American University of the Caribbean School of Medicine, 1 University Drive at Jordan Road Cupecoy, St. Maarten, Tel: 843-455-5637

**Copyright:** © 2021 Alimia E, et al. This is an open-access article distributed under the terms of the Creative Commons Attribution License, which permits unrestricted use, distribution, and reproduction in any medium, provided the original author and source are credited.

**Citation:** Alimia E, Volpe C, Cunningham J, Mohtadi M, DeTrollo V, et al. (2021) Primary Bilateral Rhabdomyosarcoma of the Breast in a young female. Report of a case with unusual clinical presentation and review of the literature. SM J Sarcoma Res 7: 3.

malignant cells with the same features as the breast masses (**Figure 1D**) Immunohistochemistry (IHC) studies revealed positivity for Desmin (**Figure 1E**), Myogenin (**Figure 1F**), Myoglobin, BCL-2, and CAM 5.2 (dot-like pattern) and negative reaction for Cytokeratin AE1/AE3, HMB-45, BREST-2, ER, PR, Cycline-D1, BCL-6, CD99, Synaptophysin and chromogranin. Additionally, fluorescence in situ hybridization (FISH) detected N-myc (MYCN) oncogene amplification. All of these results and findings were consistent with alveolar rhabdomyosarcoma. Total body imaging work up showed no evidence of malignancy elsewhere; therefore, the breast tumors were consistent with primary bilateral rhabdomyosarcoma of the breast.

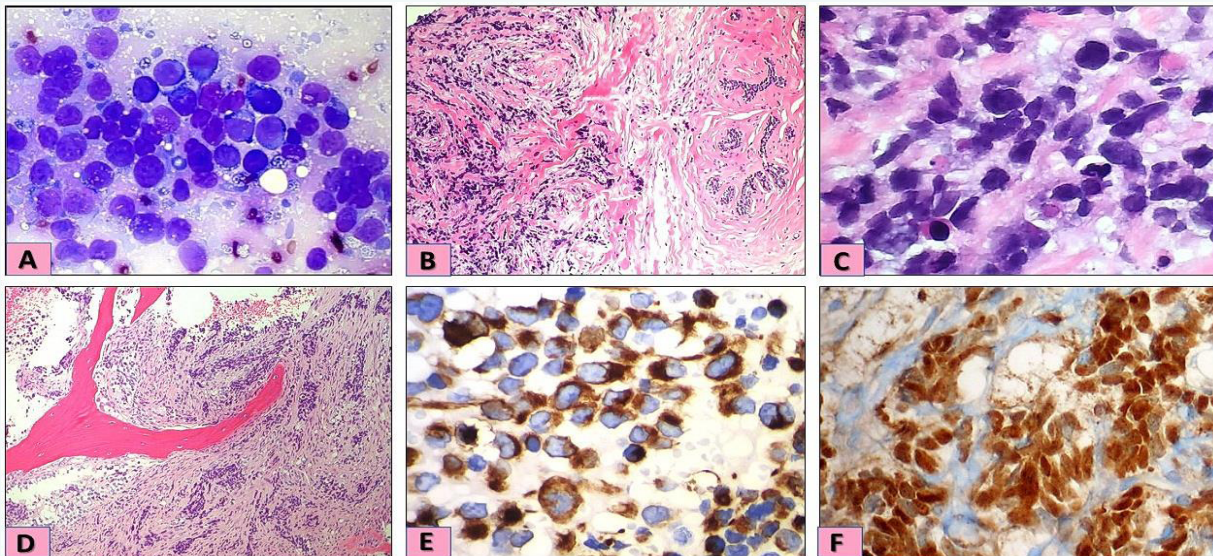
After the exclusion of metastatic origin, a bilateral mastectomy with partial removal of the pectoralis muscle was performed. The pectoralis muscle under the breast deep fascia was not involved by Rhabdomyosarcoma, which ruled out possible origin from the chest muscles under the breast and confirmed the primary origin of the tumor. Post-operative chemotherapy treatment was given, including eight cycles of second-line chemotherapy with vincristine, dactinomycin, and endoxan. Additionally, the patient received radiation therapy due to the presence of tumor cells that were in close proximity to the deep fascia.

Following chemotherapy and radiation treatment the patient was free of tumor and had no recurrence of metastasis for thirteen months. After thirteen months, the patient began showing GI and pulmonary symptoms with metastasis to the abdominal cavity, lung, and bone. Due to the metastasis, another round of chemotherapy was given. The patient expired five weeks later.

## Discussion

Cancer of the breast is the most common cancer among women. Among all breast cancer diagnoses, nonepithelial origin account for less than 5% of all breast neoplasms<sup>16</sup>. Breast sarcomas are often unilateral, well-defined, painless and firm, with lymph node involvement being rare. Most of these tumors increase rapidly in size and grow to be larger than epithelial breast tumors. Though there are clinical distinguishing factors, it is not possible to determine breast cancer cell of origin based on clinical presentation alone. Early findings of a breast sarcoma may be clinically and radiologically similar to those of benign origin, causing them to be frequently diagnosed later in an advanced stage. Tissue biopsy with immunohistochemistry confirmation is a must to make an accurate diagnosis. Proper origin and diagnosis of non-epithelial tumors is required to determine optimal treatment, which differs from tumors of epithelial origin. Due to the aggressive behavior and poor prognosis of these tumors, complete mastectomy followed by chemotherapy and possible irradiation is the treatment of choice to obtain adequate negative margins.

Rhabdomyosarcoma of the breast is extremely rare, representing 0.2% of diagnosed breast cancers.<sup>7</sup> Rhabdomyosarcoma is thought to arise from immature mesenchymal cells that are committed to skeletal muscle lineage, that is why these tumors can also arise in tissues in which striated muscle is not normally found, such as the breast.<sup>13</sup> Classification of a tumor as RMS requires identification of skeletal muscle lineage features: rhabdomyoblasts and cross striations. RMS



**Figure 1** Pathological examination of breast masses and bone marrow biopsy.

**1A:** Breast mass, fine needle aspiration smear cytology showing malignant small blue round cell tumor (DQ stain x60).

**1B:** Uninvolved breast tissue (right) infiltrated by small blue round cell tumor (left) (H&E stain x20).

**1C:** High power view of breast mass showing round, oval and polygonal to elongated tumor cells with occasional dispersed individual cells with dense nuclear chromatin and irregular nuclear membranes (H&E stain x60).

**1D:** Bone marrow biopsy showing infiltration by small blue round cell tumor (H&E stain x20).

**1E:** Tumor cells positive for Desmin.

**1F:** Tumor cells positive for Myogenin.



must be confirmed by positive staining for desmin, myogenin, and myoglobin. Heterologous rhabdomyosarcomatous differentiation, such as malignant phylloides tumors, and metaplastic breast carcinomas should be excluded before making the final diagnosis of RMS.<sup>20</sup>

RMS tumors measuring >5 cm is sensitive to radiotherapy; however, radiotherapy may increase the risk of alveolar rhabdomyosarcoma.<sup>15-17</sup> The 5-year survival rate for primary breast rhabdomyosarcoma is 43%.<sup>10</sup>

It is postulated that rhabdomyosarcoma can be either myogenic or non-myogenic. Myogenic RMS may be due to a subset of early muscle forming cells, the satellite cells. Non-myogenic RMS may be due to mesenchymal progenitor cells which are committed not only to striated muscle differentiation, but also to produce connective tissue. It is hypothesized that such non-myogenic cells may circulate in many different organs and may give rise to RMS in uncommon sites such as the breast in our case<sup>8</sup>. Myogenin positive staining tumors are more associated with the alveolar type of RMS compared to embryonal RMS and are thought to have a poorer prognosis.

Mammography at the age of 40 is the most effective screening technique. Until recently, breast self-examination (BSE) has been found to also increase survival rates.<sup>3,4,6,9</sup> However, with recent recommendations, most medical organizations don't recommend routine breast self-exams as a part of breast cancer screening. That's because breast self-exams haven't been shown to be effective in detecting cancer or improving survival for women who have breast cancer. Still, doctors believe there is value in women being familiar with their own breasts, so they understand what's normal and promptly report changes.<sup>19</sup>

We hope that this report raises awareness of what remains an unmet need in the definitive diagnosis and management of various breast malignancies. Furthermore, that the continued investigation drives further development of efficacious diagnosis and safe treatments for improving patient outcomes.

## Acknowledgment

Special thanks to Aimee Lombard, Kyle Coombes, and Amanda Kuruvilla, MD candidates, American University of the Caribbean for their assistance in reviewing the final manuscript

## References

1. Bayramoglu Z, Kebudi R, Yilmaz R, Buyukkapu Bay S, Kebudi A, Karanlik H, Iribas A, Darendeliler E, Onder S, Bilgic B, Adaletli İ: Primary Rhabdomyosarcoma of the Breast: Imaging Findings and Literature Review. *Breast Care* 2018;13:293-297.
2. Chugh MD. Breast sarcoma: Epidemiology, risk factors, clinical presentation, diagnosis, and staging. Post TW, ed. UpToDate. Waltham, MA: UpToDate Inc.
3. Costanza MC, Foster RS Jr. Relationship between breast self-examination and death from breast cancer by age groups. *Cancer Detect Prev*. 1984;7(2):103-108.
4. Early Detection of Breast Cancer. *JAMA*. 1984;252(21):3008-3011. doi:10.1001/jama.1984.03350210056032
5. Faith MD. Rhabdomyosarcoma in childhood and adolescence: Epidemiology, pathology, and molecular pathogenesis. Post TW, ed. UpToDate. Waltham, MA: UpToDate Inc.
6. Foster RS Jr, Lang SP, Costanza MC, Worden JK, Haines CR, Yates JW. Breast self-examination practices and breast-cancer stage. *N Engl J Med*. 1978;299(6):265-270. doi:10.1056/NEJM197808102990601
7. Hays DM, Donaldson SS, Shimada H, Crist WM, Newton WA Jr., Andrassy RJ, Wiener E, Green J, Triche T, Maurer HM. Primary and metastatic rhabdomyosarcoma in the breast: neoplasms of adolescent females, a report from the Intergroup Rhabdomyosarcoma Study. *Medical and pediatric oncology*. 1997;29:181-9.
8. Hettmer S, Li Z, Billin AN, Barr FG, Cornelison DD, Ehrlich AR, Guttridge DC, Hayes-Jordan A, Helman LJ, Houghton PJ, Khan J, Langenau DM, Linardic CM, Pal R, Partridge TA, Pavlath GK, Rota R, Schäfer BW, Shipley J, Stillman B, Wexler LH, Wagers AJ, Keller C. Rhabdomyosarcoma: current challenges and their implications for developing therapies. *Cold Spring Harb Perspect Med*. 2014 Nov 3.
9. Jacob TC, Penn NE. The need and value of breast self-examination. *J Natl Med Assoc*. 1988;80(7):777-787.
10. Kim, D. Y., Seol, Y. M., Kim, H., Kim, A., & Choi, Y. J. (2017). Primary rhabdomyosarcoma of the breast in a 17-year-old girl. *Medicine*, 96(49).
11. Miller AB, Chamberlain J, Tsechkovski M. Self-examination in the early detection of breast cancer. A review of the evidence, with recommendations for further research. *J Chronic Dis*. 1985;38(6):527-540. doi:10.1016/0021-9681(85)90037-2
12. O'Malley MS, Fletcher SW. US Preventive Services Task Force. Screening for breast cancer with breast self-examination. A critical review. *JAMA*. 1987;257(16):2196-2203.
13. S. Agarwala, "Pediatric Rhabdomyosarcoma and non-rhabdomyosarcoma soft tissue sarcoma," *Journal of Indian Association of Pediatric Surgeons*, vol. 11, no. 1, 2006.
14. Trihia, H. J., Novkovic, N., Provatas, I., Mavrogiorgis, A., & Lianos, E. (2019). Primary Alveolar Rhabdomyosarcoma of the Breast in an Adult: An Extremely Rare Case. *Case Reports in Pathology*, 2019, 1-6. <https://doi.org/10.1155/2019/6098747>
15. Woods GM, Bondra K, Chronowski C, et al. Radiation therapy may increase metastatic potential in alveolar rhabdomyosarcoma. *Pediatr Blood Cancer*. 2015;62(9):1550-1554. doi:10.1002/pbc.25516
16. Young, J.L.J., Ward, K.C., Wingo, P.A. et al. The Incidence of Malignant Non-Carcinomas of the Female Breast. *Cancer Causes Control* 15, 313-319 (2004).
17. Yuan Y, Hou J, Pan Y. Rhabdomyosarcoma of the breast: Report of a rare malignancy. *Cancer Biol Ther*. 2017;18(9):676-680. doi:10.1080/15384047.2017.1360440
18. Zagars GK, Ballo MT, Pisters PW, et al. Prognostic factors for patients with localized soft-tissue sarcoma treated with conservation surgery and radiation therapy: an analysis of 1225 patients. *Cancer*. 2003;97(10):2530-2543. doi:10.1002/cncr.11365
19. Scott C. Litin, and Sanjeev Nanda. *Mayo Clinic Family Health Book*. Fifth edition. 2018 Mayo Foundation for Medical Education and Research (MFMER). ISBN: 978-1-945564-02-4
20. Busch Thomas, Bayram E, Shepley Kirk, Aziz Mohamed (2018) Metaplastic Breast Carcinoma with Metastasis to Small Bowel: A Case Report with Review of the Literature. *JSM Clin Case Rep* 6(3): 1154.